

Letters to the Editor

Cause of Glenoid Rim Fracture

To the Editor:

I read with interest the article by Banerjee et al.¹ entitled “Glenoid Rim Fracture in Contact Athletes With Absorbable Suture Anchor Reconstruction” in the May 2009 issue of *Arthroscopy*. They very eloquently describe 3 patients who sustained a glenoid rim fracture caused by cysts that had developed around absorbable implants. Theoretically, however, as the authors point out, development of a cyst or any loss of bone could cause weakness in the glenoid, predisposing toward fracture if the stress is great enough. We have also seen this at our institution, and the cause of the fracture of the glenoid rim may not be associated only with the development of a cyst surrounding the implant.

The teaching over the past several years has been to move the insertion site of the arthroscopic anchor from the medial edge of the glenoid to the edge of the articular surface. To bring the capsule and labrum back onto the edge of the glenoid in an attempt to re-create the normal anatomic bumper, we have been drilling through the anterior edge of the glenoid. Theoretically, simply drilling several holes in line across the anterior glenoid

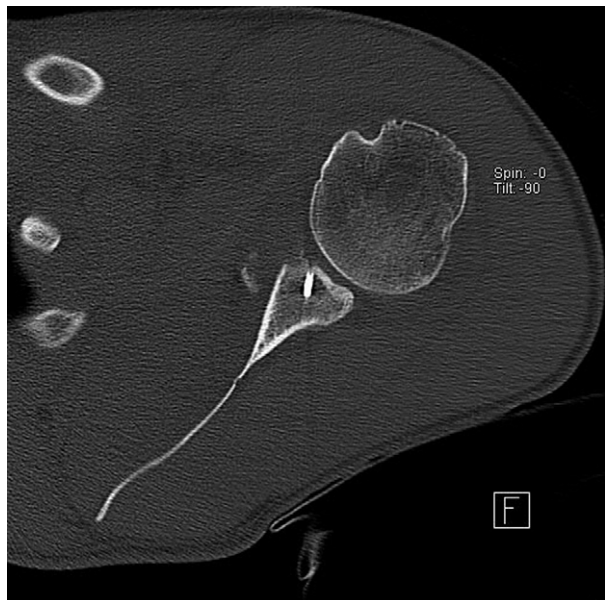


FIGURE 1. Axial computed tomography scan showing fracture of glenoid rim distal to a well-fixed anchor in a patient who had a shoulder dislocation while skiing after prior successful arthroscopic stabilization.

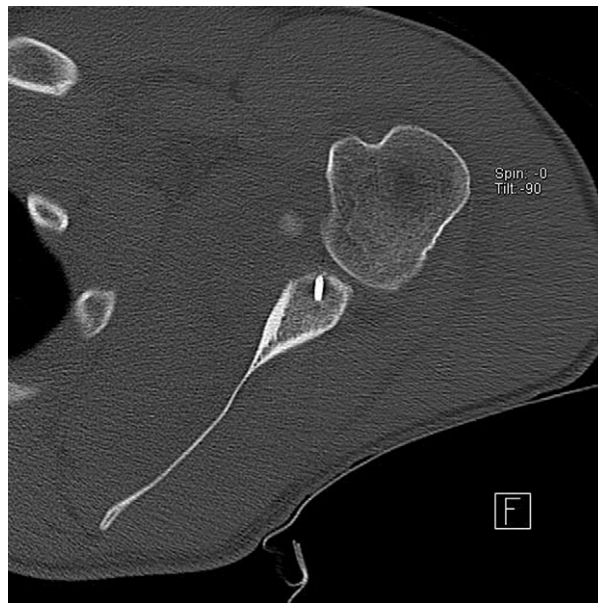

FIGURE 2. Axial computed tomography scan of inferior anchor. The glenoid rim was observed to have fractured distal to a well-fixed anchor.

would predispose the edge of the glenoid to fracture if enough stress is applied. Figures 1-3 show images from a patient with metallic anchors who sustained a glenoid rim fracture after a

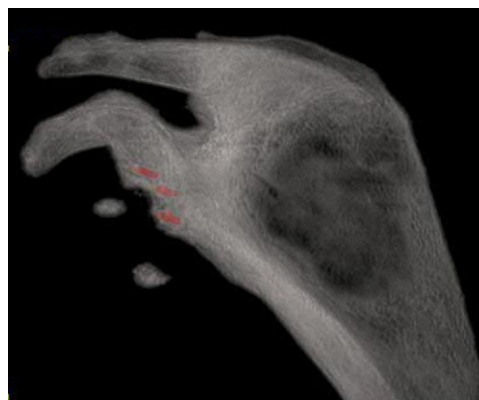


FIGURE 3. Three-dimensional computed tomography scan of glenoid with metallic enhancement technique. The fracture was observed between the middle and inferior anchors at the level of the drill holes for the 2 anchors.

redislocation while skiing after a successful arthroscopic stabilization. We were able to reconstruct this patient's glenoid with a Latarjet procedure, and he remains in stable condition.

I think it would be reasonable to assume that in addition to the theoretic weakness associated with cyst formation in the glenoid, the simple act of drilling several holes in line on the anterior edge of the glenoid would alone predispose the glenoid to fracture if enough stress is applied, as was shown in the patient we recently treated.

Scott P. Steinmann, M.D.
*Mayo Clinic
 Rochester, Minnesota*

Reference

1. Banerjee S, Weiser L, Connell D, Wallace A. Glenoid rim fracture in contact athletes with absorbable suture anchor reconstruction. *Arthroscopy* 2009;25:560-562.

© 2009 by the Arthroscopy Association of North America

doi:10.1016/j.arthro.2009.07.003

Author's Reply

We thank Dr. Steinmann for his interest in our article and were interested to read about his experience with similar cases.

From an engineering point of view, the creation of any defect (such as a drill hole) within a structure will tend to cause stress concentration around the defect, particularly if that defect lies close to the margin of the structure. If several defects lie in close proximity, a "postage stamp" effect may be created, where cracks may propagate between defects and coalesce.

We agree that the use of suture anchors necessarily incurs this risk, and whether the drill hole is initially filled with metal, polymer, or absorbable material probably does not matter. The extra concern with some absorbable implants is that the defects may enlarge unpredictably beyond their original dimensions because of osteolysis and make matters worse.

Ideally, newer materials that fully resorb and are replaced by host bone seem the best solution to restoring stress distribution across the glenoid face, but reconstitution may take several years and it is not feasible to expect athletes in collision sports to avoid competition during this process. Until we have a better solution, patients should be advised of the risk of glenoid rim fracture, irrespective of the type of anchor used.

Andrew L. Wallace, Ph.D., F.R.A.C.S.
*The Shoulder Unit
 Hospital of St. John & St. Elizabeth
 London, England*

© 2009 by the Arthroscopy Association of North America

doi:10.1016/j.arthro.2009.07.002

The Anteromedial Portal for Anterior Cruciate Ligament Reconstruction

To the Editor:

We read with great interest the discussion on the use of the anteromedial portal for anterior cruciate ligament (ACL) reconstruction.¹ Clearly, Dr. Lanny Johnson and Dr. David Shneider are forefathers of modern-day arthroscopy, and we thank Dr. Shneider for his mentorship and his dedication to advancing the field and improving patient results. With regard to the anteromedial portal approach for ACL reconstruction, we respect Dr. Shneider's experience with the use of this technique and agree with his statement that transtibial drilling could result in poor femoral tunnel positions.^{2,3}

At our institution, the medial portal approach has been used successfully for a number of years, for both single- and double-bundle reconstructions and with several femoral fixation devices. In addition, an accessory medial portal is used that allows for visualization and instrumentation from the medial side simultaneously (Fig 1).^{4,5} The 2 medial portals

are created very carefully with guidance from a spinal needle. The anteromedial portal is first established along the inferomedial border of the patellar tendon. It is angled proximally and laterally, along the path of the native ACL, and easily reaches the femoral attachment site. The accessory medial portal is established medially along the joint line as inferiorly as possible without damaging the medial meniscus. Careful visualization from the anterolateral portal ensures that there is enough space to avoid damage to the medial femoral condyle when using cannulated drills (Fig 2).^{6,7} By using this approach, we have found that the native femoral ACL insertion site is easily identified and accessed, even in those cases with narrow notch measurements (Fig 3). In our experience this has made the notchplasty largely unnecessary, whereas we performed it routinely in the past. Furthermore, when a notchplasty is performed, the native femoral ACL insertion site is removed along with important